

# Dentigerous Cyst: Radiological Perspective A Short Communication

Sarangi. R. Varma <sup>1\*</sup>, Dr. Vineet Alex Daniel<sup>2</sup>

<sup>1</sup> Intern, Annoor Dental College, Kerala, India.

<sup>2</sup> Prof. and HOD, Dept of Oral Medicine and Radiology, Annoor Dental College, Kerala, India.

**Received date:** February 17, 2023, **Accepted date:** March 15, 2023, **Published date:** May 01, 2023.

Copyright: ©2023 Sarangi. R. Varma. This is an open-access article distributed under the terms of the Creative Commons Attribution License, which permits unrestricted use, distribution, and reproduction in any medium, provided the original author and source are credited.

**\*Corresponding Author:** Dr. Sarangi. R. Varma, Intern, Annoor Dental College, Kerala, India.

## Abstract

Radicular cysts and dentigerous cysts are the two types of odontogenic cysts that are frequently seen in everyday dental practice. In addition to their developmental origin, dentigerous cysts may also have an inflammatory origin. On radiographs, peri-coronal radiolucency was found attached to the cemento-enamel junction of the impacted tooth. Three radiological types of dentigerous cysts have been reported. CT and CBCT are useful for evaluating larger lesions.

## Introduction

Commonest odontogenic cysts in order of occurrence [1]. The dentigerous (follicular) cyst is identified as one of the most common lesions of the jaws. It is generally difficult to distinguish between a small dentigerous cyst and a large dental follicle despite the availability of both radiographic and histologic information [2]. At present, identifying a cystic cavity at the time of surgery may be the only reliable way to arrive at a definitive diagnosis when radiographic and histologic features are insufficient to differentiate between a small dentigerous cyst and a large dental follicle.

## Discussion

Dentigerous cysts are benign odontogenic cysts [3]. It is

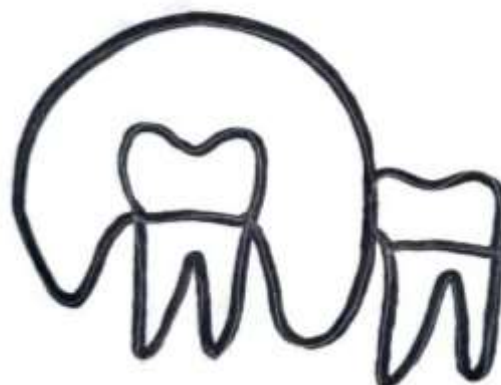associated with the crowns of unerupted teeth. This cyst occurs frequently in the mandibular third molar followed by maxillary canine region and is mostly revealed by routine radiographic inspection [4]. The dentigerous cyst can vary in size from a few millimeters to a very large lesion involving the entire body and ramus of the mandible. Perforation of the cortical plate and involvement of the overlying soft tissue can occur [5]. Large cysts may be associated with pain. Clinically, dentigerous cysts are usually asymptomatic [6]. They are typically noticeable in the third or fourth decade of life and has a slight male predominance [7]. Most dentigerous cysts are solitary. Bilateral and multiple cysts are frequently observed in syndromes like cleidocranial dysplasia and Maroteaux-Lamy syndrome [8].

## Radiological Types

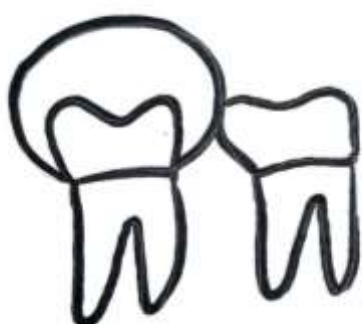There are three possible radiographic relationships between the cyst and the affected tooth:

### 1. Central variety:

- Most common radiographic type.
- The cyst develops around and surrounds the entire crown of the tooth, so the tooth appears to be erupting into the cyst



Similar radiographic characteristics can be seen in more aggressive odontogenic lesions such as odontogenic keratocysts, ameloblastomas, and other odontogenic tumours. [9]

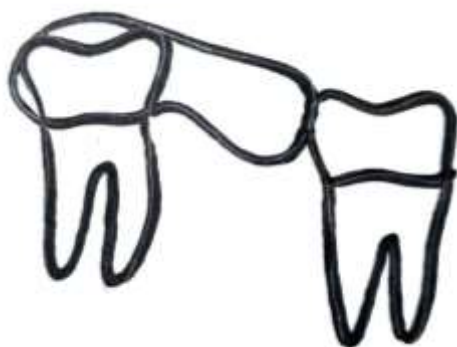


Radiographic differential diagnosis for bilateral or multifocal "cystic" lesions around impacted or partially impacted posterior teeth may include:

- Odontogenic keratocyst (keratocystic odontogenic tumor)
- Cherubism
- Bilateral buccal bifurcation cysts
- Enlarged dental follicles
- Multiple hyperplastic calcifying follicles
- Mucopolipidosis Type III, or pseudo-Hurler polydystrophy
- Maroteaux-Lamy syndrome
- Amelogenesis imperfecta
- Tuberous sclerosis or cleidocranial dysplasia

### 2. Lateral variety:

The cyst partially surrounds the crown of the tooth and extends along the side of the root.



### 3. Circumferential:

The cyst develops around the crown and extends down the root(s); thus, roots also appear within the cyst.

## Radiological Features

Radiographically, dentigerous cysts can appear as well-defined, unilocular or multilocular, well-corticated radiolucent lesions due to the absence of mineralization and are often associated with the crown of an impacted or unerupted tooth. It

is most seen around the third molar. It is mostly attached to the unerupted tooth, with the crown protruding into the cyst and the roots remaining outside the cystic lesion. Normally, a pericoronal radiolucency that has a diameter larger than 3 to 4 mm is considered to be a cyst.

Dentigerous cysts present a slow, painless swelling and can cause tooth displacement or root, teeth and bone resorption as they grow.

Paresthesia of the inferior alveolar nerve is the most frequent clinical consequence. Significant cortical expansion or thinning of the buccal and lingual cortical plates may be seen in the case of larger lesions. They can protrude into the maxillary antrum or mandibular canal or infratemporal fossa [10]. CT and CBCT are useful to evaluate larger lesions, their relationship with adjacent structures, and the integrity of the cortical plate.

### Treatment and Prognosis

The entire cyst as well as the surrounding, unerupted tooth must typically be removed as part of the treatment. Marshupialization is an option for patients with a large lesion or who are medically compromised. Recurrence is rare but could occur if some of the cyst lining is left in place.

### Complications

- A pathological jaw fracture may result if the cyst is large in size.
- In rare cases, dentigerous cysts may transform into mural ameloblastoma.
- In cases of chronic infection, squamous cell carcinoma has the potential to develop.

### Differential Diagnosis

When small, it is difficult to distinguish a dentigerous cyst from a large but normal dental follicle. When large, the differential diagnosis is essential with the purpose of distinguishing from of lytic lesions of the jaw like:

- Radicular cyst (periapical cyst)
- Ameloblastoma

- Odontogenic keratocyst (OKC)
- Aneurysmal bone cyst (ABC)
- Cherubism (familial fibrous dysplasia)
- Stafne cyst

### References








1. Sridevi K, Kaushik A, Ramaswamy P, Manjula M, Vinod VC, Aravinda C. Dentigerous cysts of maxillofacial region—clinical, radiographic and biochemical analysis. *Kathmandu University Medical Journal*. 2015 Oct 20;13(1):8-11
2. Janardhanam Dineshshankar MD, Sahuthullah Yasmeenahamed MD, Shivakumar Sivaraman MD. Radiological and Pathological Characteristics of Mandibular Cystic Lesion—A Review.
3. Ustuner E, Fitoz S, Atasoy C, Erden I, Akyar S. Bilateral maxillary dentigerous cysts: a case report. *Oral Surgery, Oral Medicine, Oral Pathology, Oral Radiology, and Endodontology*. 2003 May 1;95(5):632-5
4. Zerrin E, Husniye DK, Peruze C. Dentigerous cysts of the jaws: clinical and radiological findings of 18 cases. *Journal of Oral and Maxillofacial Radiology*. 2014 Sep 1;2(3):77.
5. Norris LH, Piccoli P, Papageorge MB. Multiple dentigerous cysts of the maxilla and mandible: report of a case. *Journal of Oral and Maxillofacial Surgery*. 1987 Aug 1;45(8):694-7.
6. Daley TD, Wysocki GP. The small

- dentigerous cyst: a diagnostic dilemma. Oral Surgery, Oral Medicine, Oral Pathology, Oral Radiology, and Endodontology. 1995
7. Bharatha A, Pharoah MJ, Lee L, Tay KY, Keller A, Yu E. Pictorial essay: cysts and cyst-like lesions of the jaws. Canadian Association of Radiologists' Journal. 2010 Jun;61(3):133-43
  8. Ko KS, Dover DG, Jordan RC. Bilateral dentigerous cysts--report of an unusual case and review of the literature. Journal of the Canadian Dental Association. 1999 Jan 1;65(1):49-51.
  9. Yoshiura K, Weber AL, Runnels S, Scrivani SJ. Cystic lesions of the mandible and maxilla. Neuroimaging Clinics. 2003 Aug 1;13(3):485-94
  10. Devenney-Cakir B, Subramaniam RM, Reddy SM, Imsande H, Gohel A, Sakai O. Cystic and cystic-appearing lesions of the mandible. American Journal of Roentgenology. 2011 Jun;196(6 SUPPL.):WS66-77



© The Author(s) 2023. This article is distributed under the terms of the Creative Commons Attribution 4.0 International License (<http://creativecommons.org/licenses/by/4.0/>), which permits unrestricted use, distribution, and reproduction in any medium, provided you give appropriate credit to the original author(s) and the source, provide a link to the Creative Commons license, and indicate if changes were made. The Creative Commons Public Domain Dedication waiver (<http://creativecommons.org/publicdomain/zero/1.0/>) applies to the data made available in this article, unless otherwise stated.

**Ready to submit your research? Choose RN and benefit from:**

-  Fast, convenient online submission.
-  Thorough peer review by experienced researchers in your field.
-  Rapid publication on acceptance.
-  Support for research data, including large and complex data types.
-  Global attainment for your research.
-  **At RN, research is always in progress.**
-  **Learn more:** [researchnovelty.com/submission.php](https://researchnovelty.com/submission.php)

